


# Approach to Multitrauma in Children

نهج لفهم حالات الأطفال المصابين  
بإصابات وجروح متعددة

Tim Horeczko, MD, MSCR, FACEP, FAAP  
Harbor-UCLA Medical Center  
@EMtogether



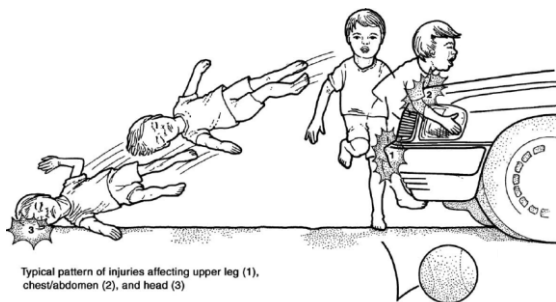
5 yo boy

Auto at 60 kph



HR 160 BP 90/60 RR 18 SpO2 93% on mask


## Waddell's Triad



## Primary Survey

Airway open,  
diminished left  
breath sounds

Ecchymosis  
Left abdomen



Deformity  
left thigh

### Secondary Survey

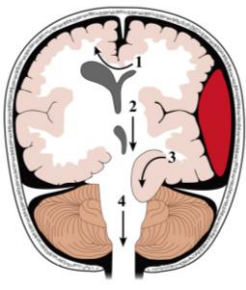
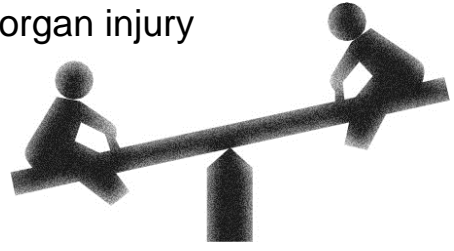GCS 8  
AVPU



Pulses throughout

### Head Injury

Abdominal solid organ injury

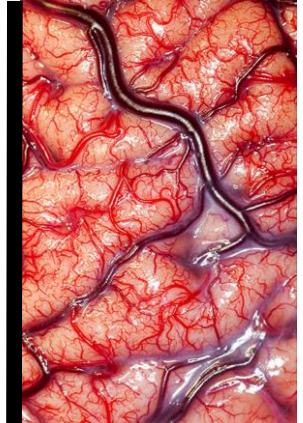

### Initial Injury

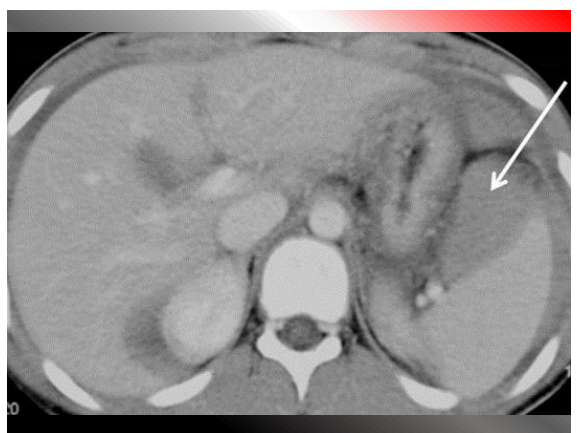
- HOB 30°
- Mannitol
- 3% NaCl
- Hypervent

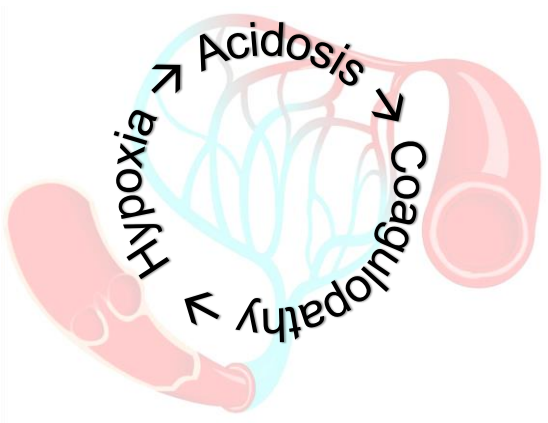
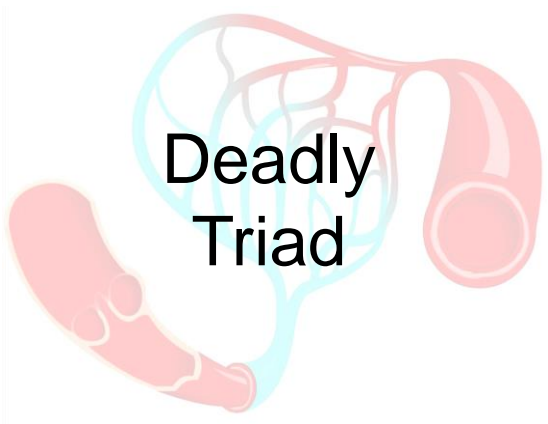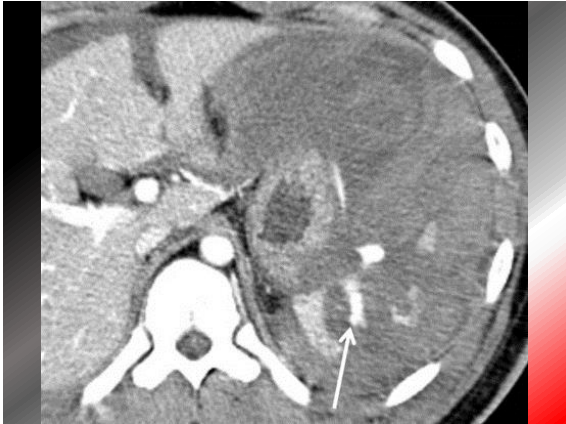### Secondary Injury

- Avoid:*
- Hypotension
- Hypoxia
- Acidosis

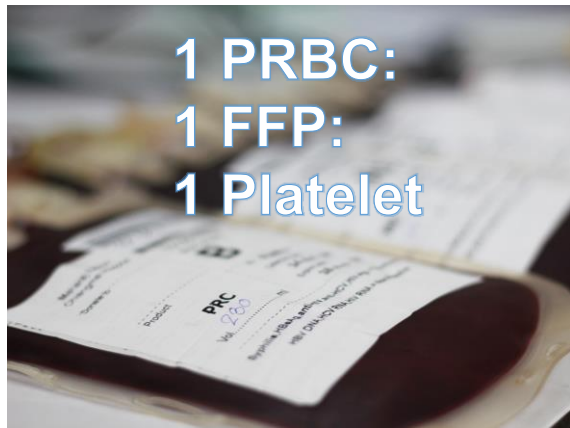
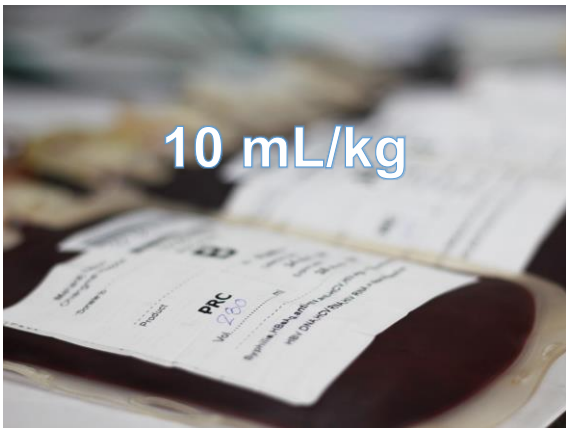
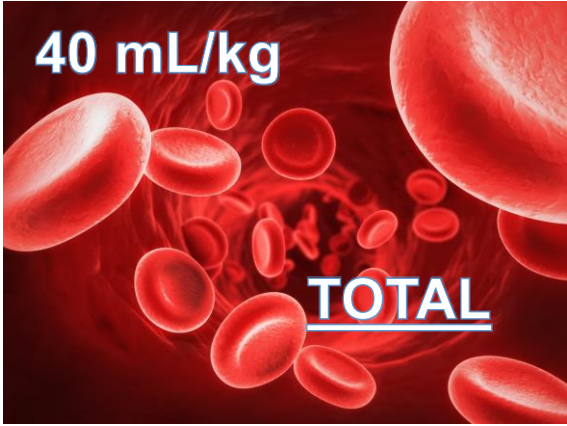## Non-Operative Management



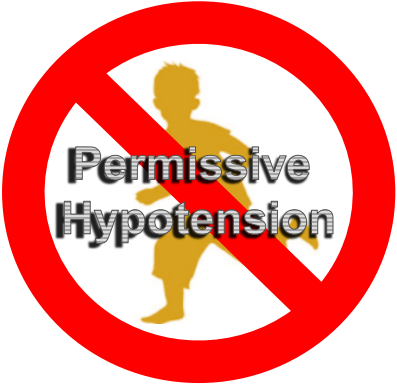

# Massive Transfusion Protocol

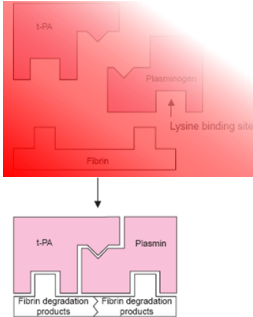


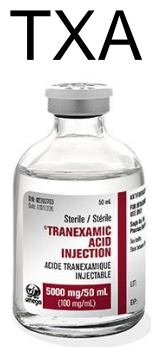
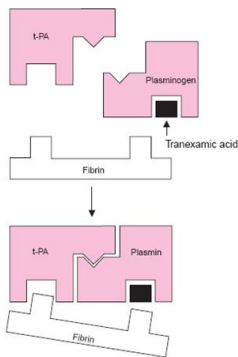


**Permissive Hypotension**

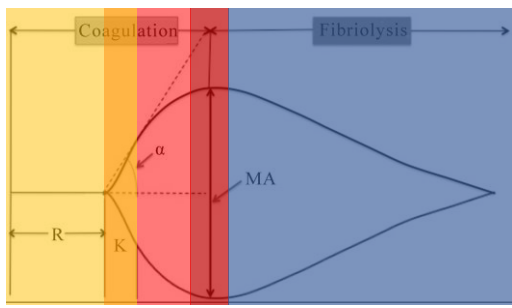


**Adjuncts**

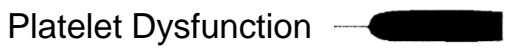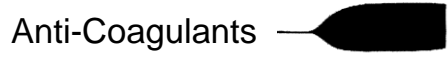
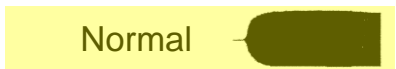




# Thromboelastogram (TEG)



- Normal
- Anti-Coagulants
- Platelet Dysfunction
- Fibrinolysis



Subdural hematoma



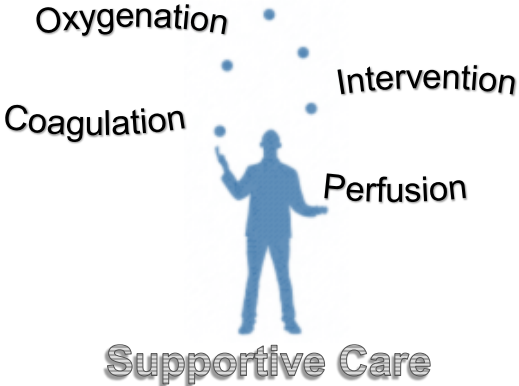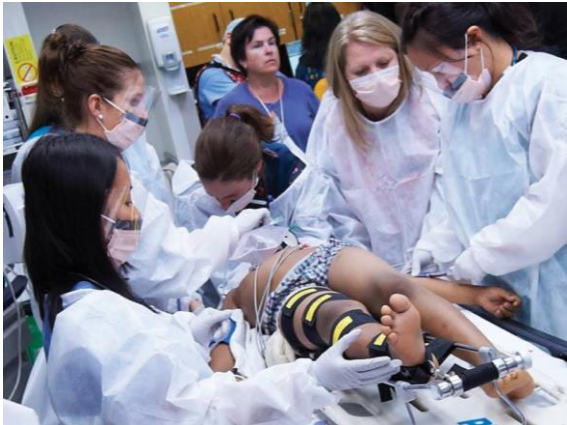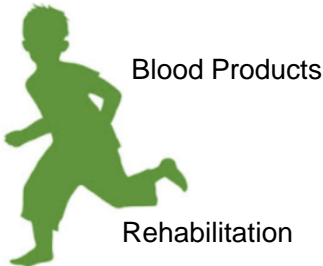Grade III Splenic Laceration

Distal Femur Fracture

ETI, Evacuation



Extubated



الأفعال أبلغ من الأقوال

"Actions speak louder than words."

شكرا

Thank you